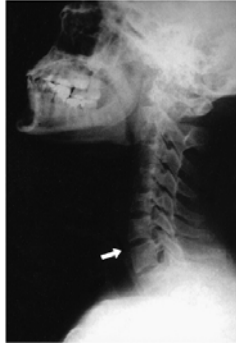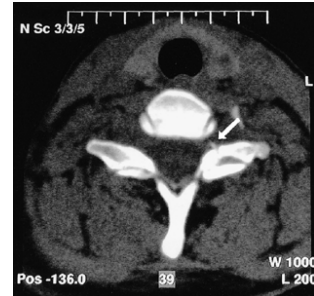


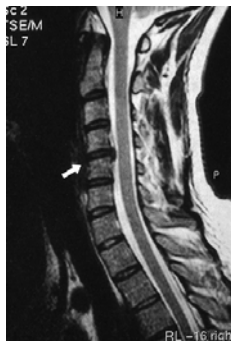Case 1
Cervical lateral plain radiograph revealed loss of the normal cervical lordosis



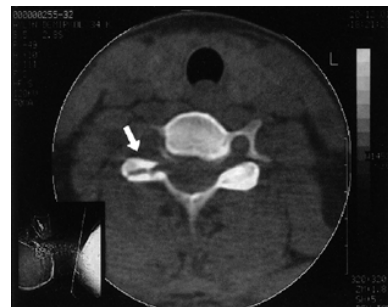Case 1. Left C6-7 facet fracture on cervical computerized tomography and small bony fragment obliterating the foramen was observed



Case 1. Minimal disc protrusion was observed on the sagittal sequences of cervical MRI examination.

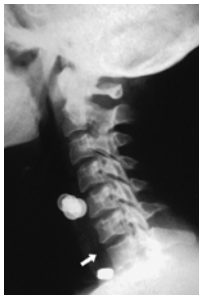

Case 2. Right C6-7 facet fracture was observed on cervical computerized tomography



Case 2. Dislocation or angulation was not observed on the cervical lateral plain radiograph obtained with collar on the

15th day



Case 2. In the preoperative cervical MRI examination, anterior longitudinal ligament rupture was identified on T1-weighted sequences

