A-B-C-D-E-F

- Adequacy (occiput-T1), Alignment (4 lines)
- Bones (vertebrae)
- Cartilage (discs, epiphyses, ossification centers)
- Dens
- Extra-axial soft tissue (pre-vertebral, pre-dental)
- Facet

Adequacy

- Skull base
- C1-C7
- Upper T1

The most common reason for a missed cervical spine injury is a cervical spine radiographic series that is technically inadequate

Swimmer's View

Adequacy

- Three views:
  1. true lateral view
  2. AP view
  3. open-mouth odontoid view
- Swimmer's view
- Portable cross-table lateral view
  - should not be obtained (frequently inadequate)

Alignment

- Anterior spinal line
- Posterior spinal line
- Spinolaminal line
- Spinous process tips

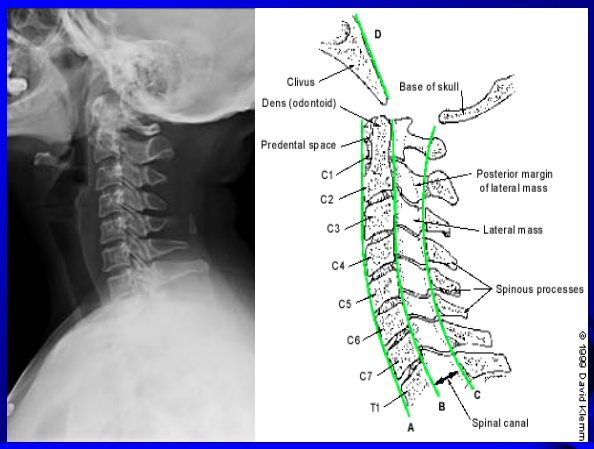

Alignment

- Anterior vertebral line
- Posterior vertebral line
- Spinolaminal line
- Spinous process tips

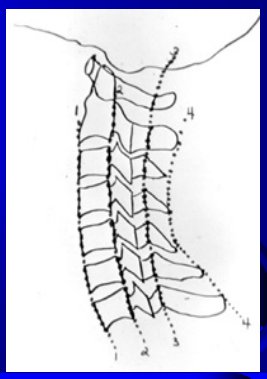

Bones

Bones

Bones

- Anterior components
  - Vertebral body (cortices, endplates)
  - Transverse process

- Posterior components
  - Articular masses and pedicles
  - Facet joints
  - Lamina
  - Spinous process

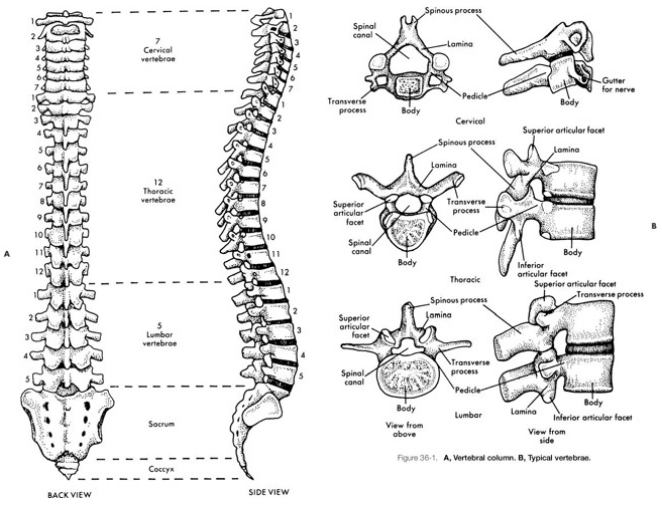

Figure 36-1. A, Vertebral column. B, Typical vertebrae.

Cartilage

- Intervertebral discs
- Epiphyses (childhood)
  - Subdental synchondrosis
- Ossification centers (childhood)
  - Tapered anterior vertebrae
  - Absent C1 anterior ring

Extra-axial Soft Tissue

Parameter	Adults	Children
Predental space	< 3 mm	< 5 mm
Prevertebral space - C2	< 7 mm	< 1/2 vertebral body
Prevertebral space - C6	< 21 mm	< 1 vertebral body
Angulation	< 11 degrees	< 11 degrees
Cord dimension	10 to 13 mm	Adult size by 6 yr

Soft tissue

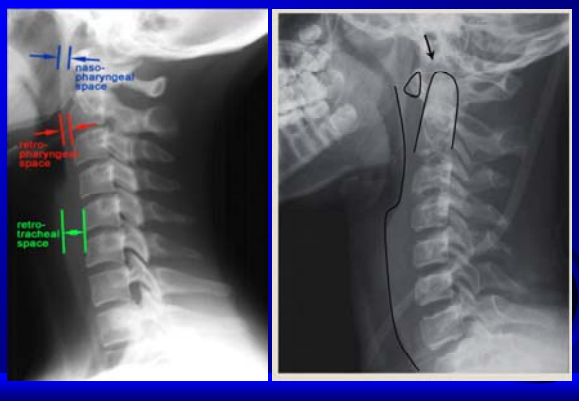

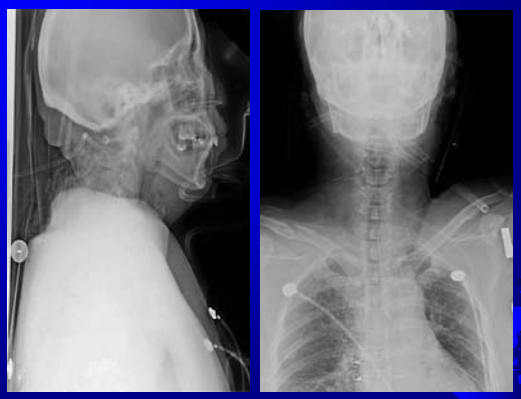

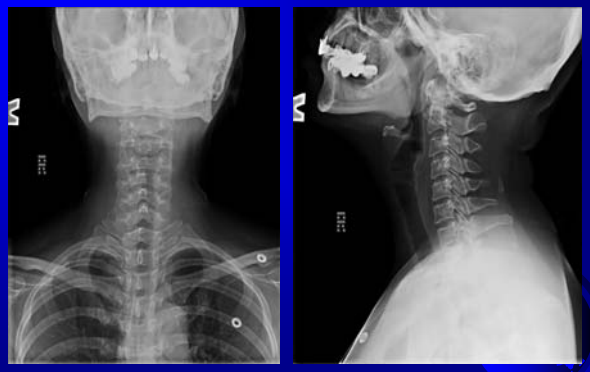

Subluxation

- Angulation between two adjoining vertebrae > 11 degrees
- Overriding of vertebra by > 3 mm

C2/3 Subluxation

C2 posterior spinal line v.s. Swischuk line

- Pseudosubluxation (< 8-16Y) :
  - Displacement < 1.5-2 mm
- Hangman fracture :
  - Displacement > 1.5-2 mm

Case: 6-year-old boy

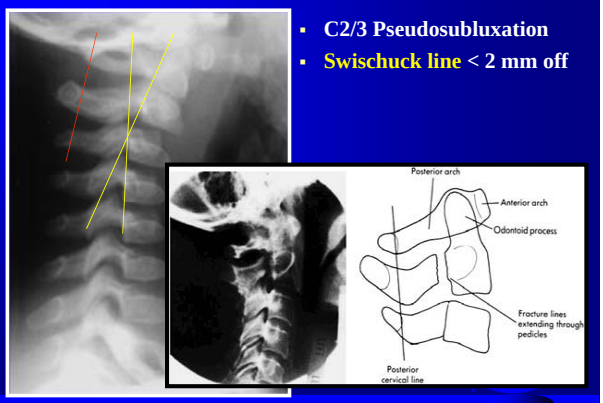

- **C2/3 Pseudosubluxation**
- **Swischuck line < 2 mm off**

Odontoid View

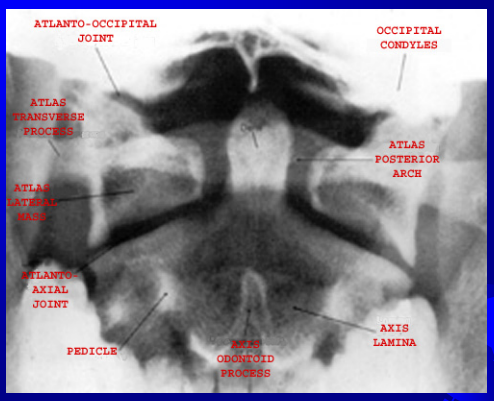

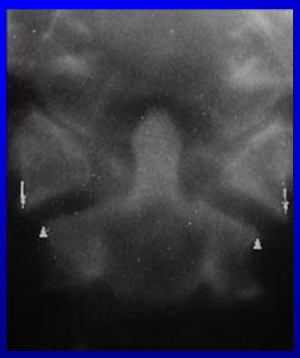

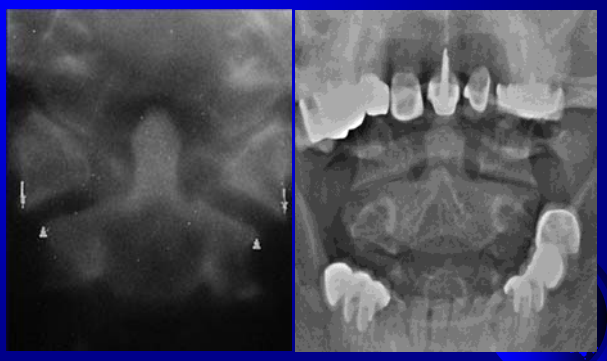

Jefferson fracture (C1)

- Blowout of the ring
- Axial loading
- Open-mouth (odontoid) view
- 1/3 associated with C-2 fracture
- Unstable
- Usually not associated with cord injury
- Lateral offset of C1 lateral masses > 1mm from C2 vertebral body

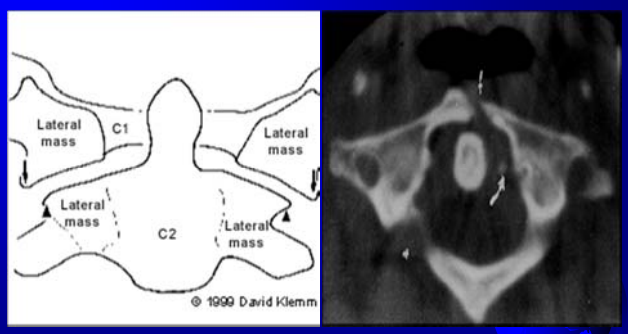

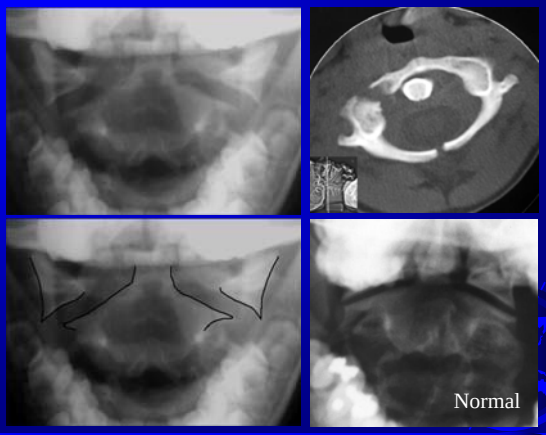

C-1 Rotary Subluxation

- Odontoid not equidistant from lateral masses
- Children
- Torticolis (chin toward uninvolved side)
- Immobilize in place
- Consult NS

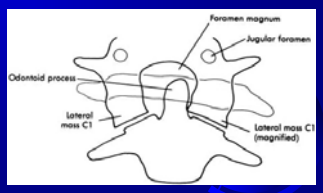

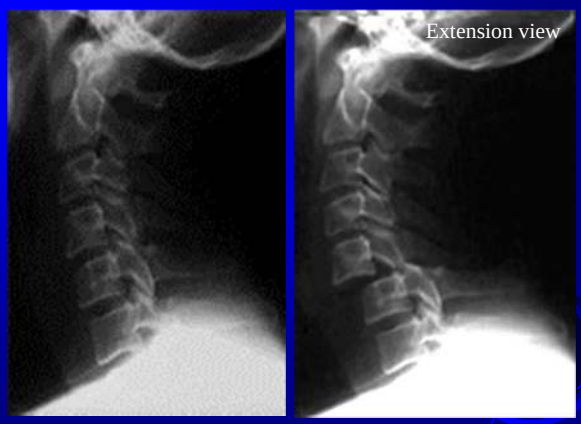

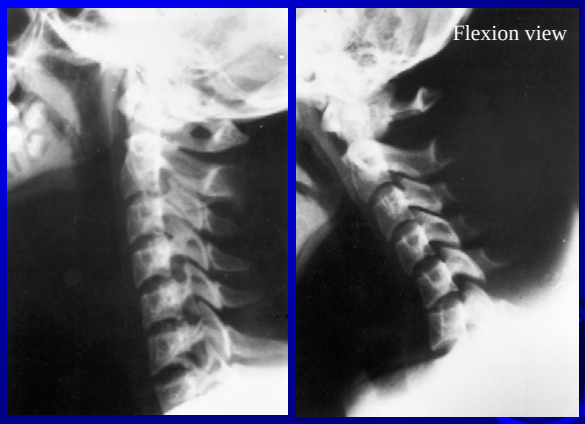

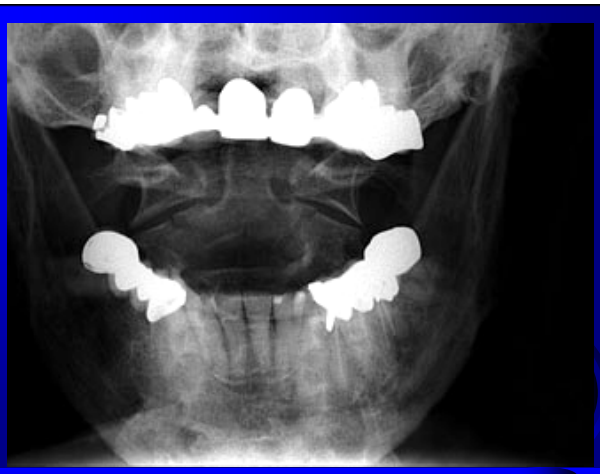

Odontoid Subluxation / dislocation

- Ruptured transverse ligament
- Predental space :
  - Ad > 3mm
  - Pd > 5mm (symptomatic if > 7-10mm)
- Odontoid fractures
- C1 spinal canal (Steel rule of 3) :
  - Odontoid – Free space – Cord
- Unstable

Odontoid Fractures

- Type I : Avulsion of tip
  - Stable
- Type II : At the base
  - Unstable
  - D/D : Synchondrosis if < 6Y
- Type III : Through vertebral body
  - Unstable

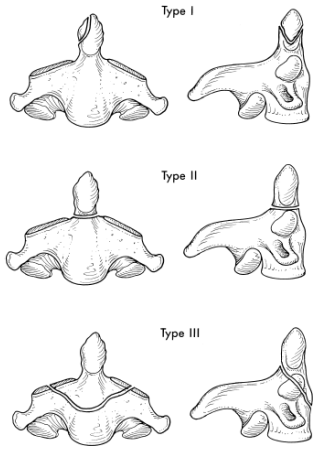

- type I - involves only the upper part of the dens
- type II (most common) - occurs where the dens and the vertebral body join
- type III - through the upper body C2 vertebra
- Some odontoid fractures can be treated with external support (such as C collar or halo traction) alone while others (especially type II) require surgery

Hangman Fracture

- Traumatic spondylolisthesis of C2
- Mechanism :
  - Extension + Distraction
  - Extension + Axial compression
- X-ray : C2/3 subluxation
- Unstable
- Traction contraindicated

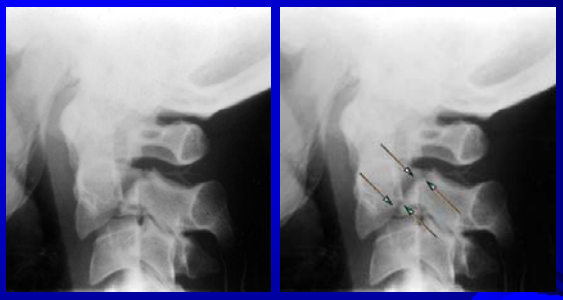

Hangman fracture - a hyperextension injury involving bilateral pars interarticularis fractures of the axis

使用鏟子工作的人

Clay shoveler fracture

C7>C6>T1

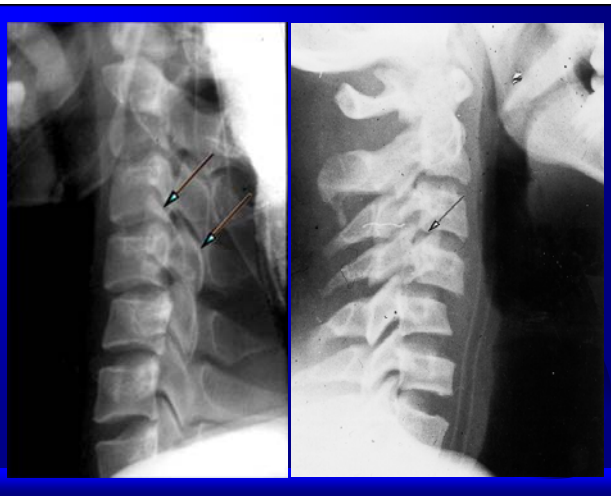

- Unilateral Facet Dislocation (Bowtie Sign)

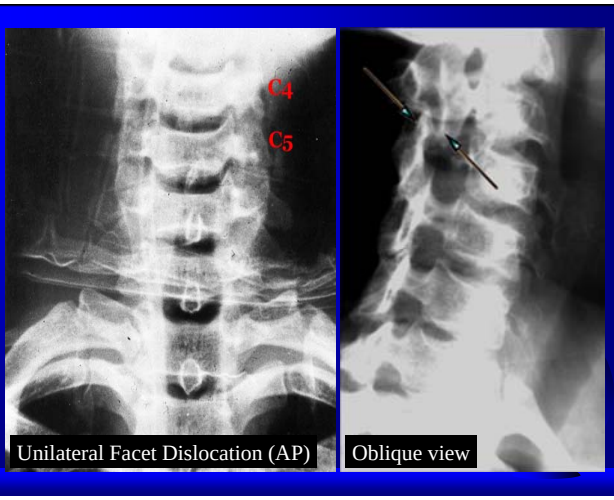

Unilateral Facet Dislocation (AP)

Oblique view

- Bilateral Facet Dislocation

Facet Dislocation

- Unilateral (UFD) :
  - Stable
  - < 25% translation
- Bilateral (BFD) :
  - Unstable
  - > 50% translation

Flexion teardrop

Extension teardrop

Teardrop Fractures

- Extension teardrop :
  - Stable in flexion, unstable in extension
  - Cortices : Same length
- Flexion teardrop :
  - Extremely unstable
  - Cortices : Unequal length

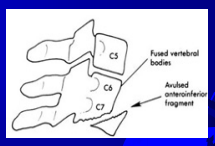

Wedge fracture of C5

Interspinous widening*

Narrowed C5-C6 intervertebral disc space

Burst Vertebral Body

- Mechanically stable
- Spinal cord injury can occur (even total transection)

Atlanto-occipital dislocation (AOD)* - longitudinal distraction with separation of the occiput from the atlas

Gap between occipital condyles and atlas > 5 mm

Fracture lines:
Odontoid type II
Mandibular ramus

Oblique C-spine

- Pedicles
- Articular mass
- Intervertebral foramen
- Transverse process
- Laminae - aligned in the fashion of shingles

Oblique views show the ***pedicle*** in profile, and also allows assesment of the ***intervertebral foramina*** (and osteophytes encroaching along their margins)

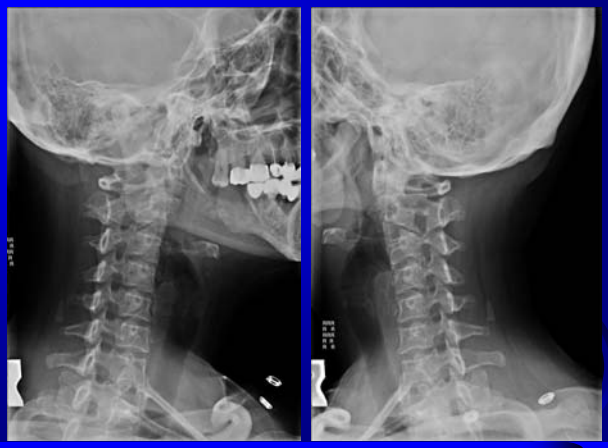

SCIWORA

- Spinal Cord Injury WithOut Radiographic Abnormality
- 67%-80% of pediatric SCI
- Mainly < 8 Y
- Plain films / tomograms / CT (-)
- May have transient neurologic symptoms and apparently recover then return 1d later with significant neurologic abnormalities
- Poor prognosis

SCIWORA

- Etiology :
  - Vascular injuries (occlusion, spasm, infarction)
  - Ligamentous injury
  - Disc impingement
  - Incomplete neuronal destruction

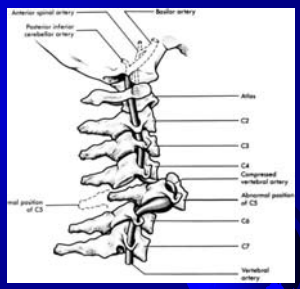

Spinal EDH

- Venous bleeds
- Minor traumas
- Ascending neurologic symptoms
- Hours or days
- MRI

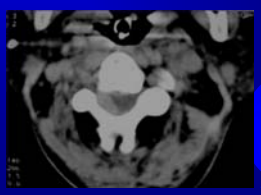

Clear neck collar

SPINAL

- **Severe pain**
- **Point of tenderness**
- **Injury mechanism**
- **Neurologic deficit**
- **Altered level of consciousness**
- **Limitation of motion**

Thank You