Right ECG

Wang, Tzong-Luen
MD, PhD, JM, FESC, FACC, FCAPSC

Professor, Medical College, Fu-Jen Catholic University
Chief, ED, Shin-Kong Wu Ho-Su Memorial Hospital
CEO, National Resuscitation Council, Taiwan
Executive Board, Taiwan Society of Emergency Medicine
Emeritus President, Society of Critical Care and Emergency Medicine
President, Taiwan Society of Disaster Medicine

Contents

- Review the pathophysiology and ECG signs of pulmonary dysfunction
- Review the ECG findings in patients with:
  - COPD
  - Acute Pulmonary Embolism
  - Pulmonary Arterial Hypertension
  - Pneumothorax and post-Penumonectomy
  - Common Congenital Cardiac Defects as seen in adults: ASD, VSD, PDA, and VPS

RAE vs. P Pulmonale: Are they the same?

- Right atrial anlargement
  - P-wave axis ≥+75' (low specificity)
  - P-wave > 0.15mV in V1 or V2 (best criteria)
- P Pulmonale (frequently indicative of transient PA strain/dilatation)
  - Peaked P-waves ≥0.25mV in II, III, or aVF
  - P-wave axis ≥+75'
- Note:
  - Degree of P-wave axis correlated better with lung disease severity than P-wave amplitude
  - P-wave amplitude correlates better with RA strain (may be transient)
  - Overlap of the two criteria

Lead II P-Wave Amplitude during COPD Exacerbation and after Treatment (50 pts.)

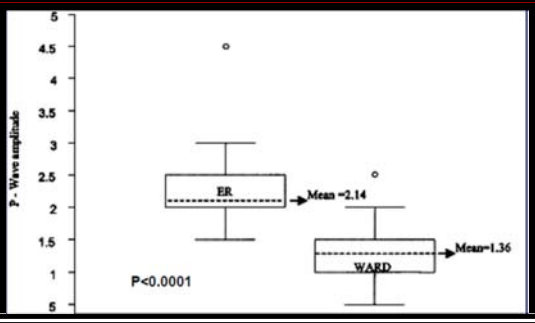

Assad et al. Chest 2003

12 Lead ECGs of Patient with COPD Exacerbation Before and After Treatment

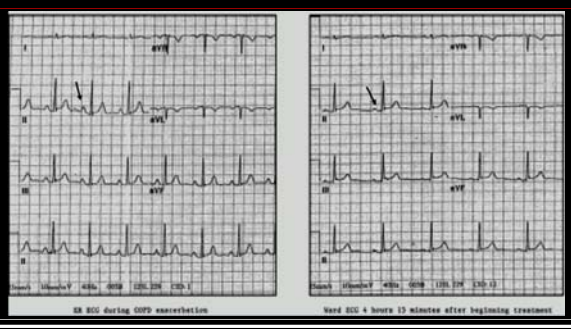

94 yo Female with CAD and Chronic Bi-ventricular CHF: LAFB, LVH, SMI, RAE (P > 0.15 mV in V1)

44 yo Male with 60 pack-year smoking: P Pulmonale (P >0.25 mV in II) No RAE by V1 criteria or by echo

Right Ventricular Hypertrophy Criteria

- RAD ≥ +110 degrees
- R/S ratio in V1 or V3R > 1
- qR in V1 or V3R (usually seen in severe RVH)
- rSR' in V1 with R' > 0.7 Mv
- R/S ratio in V5 or V6 ≤ 1
- R-wave in V1 > 0.7 mV
- S-wave in V2 < 0.2 mV
- Onset of intrinsicoid deflection in V1 > 35 ms
- Note: Need at least two criteria for definite dx.

Right Ventricular Hypertrophy

- The types of RVH correlate with severity and specific disorders (but with a lot of overlap):
  - Type A – severe RVH as seen in severe PAH, endstage COPD, severe VPS
  - Type B – mild to moderate RVH (must differentiate from true posterior MI)
  - Type C – moderate RVH as seen Mitral Stenosis, or moderate COPD and occasionally in ASD
  - IRBBB – moderate RVH or RVOT hypertrophy as seen in ASD, moderate COPD
  - Note: All types of RVH are usually associated with some degree of RAD

Normal Horizontal Vector Loop with Projection on the Precordial Lead Axis

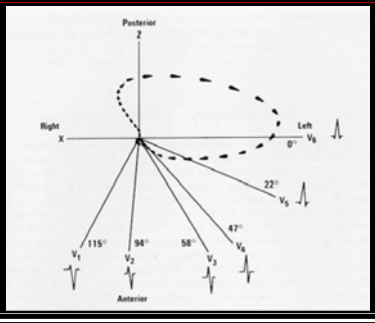

Type A RVH: Horizontal Plane VCG

Posterior

Right

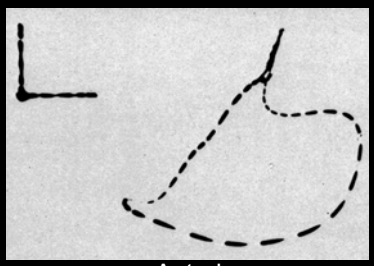

Left

Anterior

34 yo Female with Severe PA Hypertension RAD, RVH (with 20 ST abnormality), RAE

Type B RVH Horizontal Plane VCG

Posterior

Right

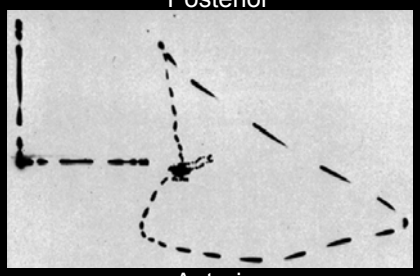

Left

Anterior

57 yo Female
Type B RVH or Posterior MI?

Type C RVH Horizontal Plane VCG

Posterior

Right

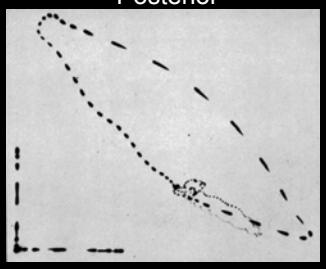

Left

Anterior

38 yo Female with MS: Type C RVH, ±LAE

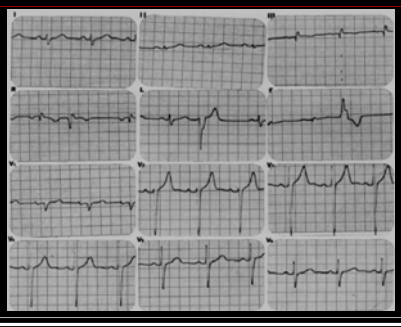

66 yo Male with severe COPD
Type C RVH with IRBBB, RAE, P Pulmonale

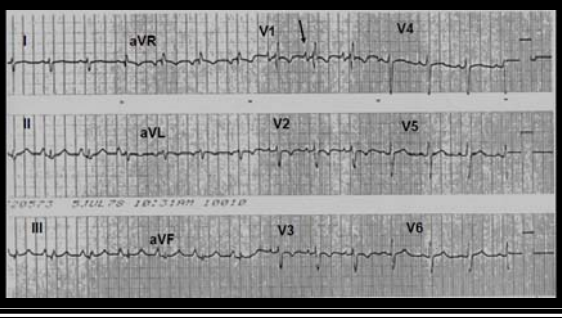

Pathophysiology and the ECG in COPD

- Intermittent hypoxia and pulm.asoconstriction
- Right atrial "strain"
- Right atrial enlargement
- "Clockwise" rotation of the heart
- RVH (usually mild or mod. unless end-stage)
- Lung hyperinflation
- Depressed diaphragms
- Rightward QRS axis
- P Pulmonale (peaked & >0.25 mV) in II, III, Avf
- Shift of transition leftward*
- Low voltage in limb leads
- Type B or C RVH (late)
- Transient atrial arrhythmias (MAT is pathognomonic) during decompensation.

*** The "poor precordial R-wave progression" sign is least specific**

ECG Criteria for COPD (Chou)

- P pulmonale (peaked P ≥ 0.25 mV in II, III, aVF)
- P wave axis ≥ +80^0
- QRS amplitude ≤ 0.5 mV in all limb leads
- QRS axis > +90^0
- QRS amplitude ≤ 0.5 mV in V_5 , V_6
- S1S2S3 pattern with R/S < 1 in I, II, III
- Atrial arrhythmias (especially MAT)

◆ COPD likely to be present if one P and one QRS criterion present

ECG Criteria for COPD (other investigators)

- P-wave axis > +70^0 = 89% sensitive and 96% specific
- Degree of QRS RAD correlated with but QRS axis > +90^0 in only 8%
- Others report P axis > + 60^0 in 60% of cases
- S1S2S3 pattern in only 25 % of
- Leftward QRS transition with R/S < 1 in V_5 V_6 (type C RVH) = severe (end-stage) COPD

◆ Reasons for differences: Most studies are observational with no echo or anatomic correlation and COPD is a dynamic disease

Sensitivity and Specificity of these ECG Criteria

- For single criterion – specificity is low (54% false positive)
- With two or more criteria specificity much better. Example:

  With P-wave axis ≥ +80^0 and QRS axis ≥ +90^0 or low voltage QRS or R/S in V5/V6 <1, specificity was 100% in study of Kamper et al

63 yo Male with Severe Emphysema: (Residual Volume: 171% of predicted) P Pulmonale, P axis +85^0, limb lead QRS≤0.5 mV

69 yo Male with COPD QRS axis > +90^0, Limb Lead Low Voltage, Transition Shifted Leftward

Multifocal Atrial Tachycardia with Block in Patient with COPD (note at least 3 different P Wave Morphologies

Acute Pulmonary Embolism: Pathophysiology and ECG Findings

- Sympathetic stimulation
- Acute pulmonary hypertension
- RA & RV strain/dilatation
- Spatial changes (clockwise rotation)
- ↑ RV wall stress leading to RV ischemia
- RV dysfunction
- Sinus tachycardia
- P Pulmonale
- RBBB (complete or incomplete)
- Acute rightward axis shift
- S1Q3T3 pattern (? IMI)
- ↓ T V1-V3 (frequently persistent) (? ASMI)
- Atrial arrhythmias (AFib or A Flutter)

Acute Pulmonary Embolism: Incidence of ECG Findings (various series)

- Sinus tachycardia: 8-73%
- P Pulmonale: 6-33%
- Rightward axis shift: 3-66%
- Inverted T-waves in ≥ 2 Rt chest leads: 50%
- S1Q3T3 pattern: 11-50%
- S1 – 60%, Q3 – 53%, ↓T3 – 20%
- Clockwise rotation: 10-56%
- RBBB (complete or incomplete): 6-67%
- AF or AFlutter: 0-35%
- No ECG changes: 20-24%
  - These changes are frequently transient resulting in a wide range of incidence

Pulmonary Embolism: ECG Score

Score > 9 suggests PA syst. Pressure>50 (Daniel; Chest 2001) and correlates with amount of perfusion deficits (Iles; Chest 2004)

Characteristics	Score
Tachycardia (> 100 beats/min)	2
Incomplete right bundle-branch block*	2
Complete right bundle-branch block†	3
T-wave inversion in lead V_1 through V_4	4
T-wave inversion in lead V_1, mm	
< 1	0
1-2	1
> 2	2
T-wave inversion in lead V_2, mm	
< 1	1
1-2	2
> 2	3
T-wave inversion in lead V_3, mm	
< 1	1
1-2	2
> 2	3
S wave in lead I‡	0
Q wave in lead 3§	1
Inverted T wave in lead 3	1
If all of S1Q3T3	2
Total score (maximum = 21)	

39 yo M with Major PE (Thrombi in both R. & L. main PAs, RV Dysfunction by Echo)

Sinus tachycardia and shift in transition the only ECG abnormality

57 yo F. with Massive PE (Severe RV dysfunction by Echo) DDx: Anterior wall ischemia

↓ T-waves in V1-V4 and leftward displaced transition are the only ECG findings here

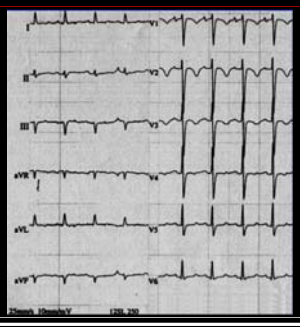

Prognostic Significance of T Wave Inversion in Acute PE

Number of Leads with T Wave Inversion:	RV dysfunction incidence (echo):
≤ 3	47%
4-6	92%
≥ 7	100%

Kosuge et al. Circ J 2006

67 yo Male with Massive PE; no MI

Initial diagnosis was acute anterior STEMI

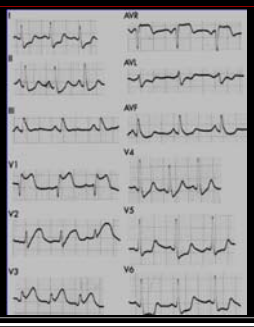

Post Pneumonectomy Changes New IRBBB, New ST & T Abnormalities V1-V3

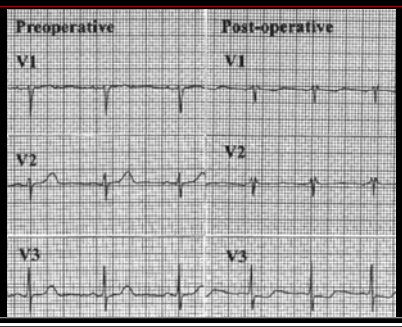

ECG Changes in Pneumothorax

- Depend on the size of the pneumothorax
- Caused by displacement of the heart
- Most often RAD, independent of the pneumothorax site
- Low voltage frequently present
- QS complexes in precordial leads also common
- T-wave inversions simulate ischemia
- Occasionally ST elevations mimic injury

44 yo Male Developed Severe Chest Pain and Dyspnea while Jogging

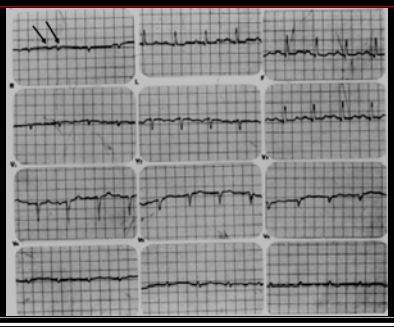

Same Patient after Left Chest Tube Inserted

ECG Findings Pulmonary Hypertension

- Depend on:
  - Severity and duration of the process
  - Whether PH is primary (PAH) or secondary to other conditions (e.g. Mitral Stenosis)
  - Primary: various degrees of RVH
  - Secondary: combination of RVH and other findings (e.g. in MS: RVH and LAE)

27 yo Female with Severe PAH
Type A RVH: Marked RAD, qR in V1 (R=1.9 mV)

ECG Changes in Selected Congenital Defects

ECG Findings in ASD

- Secundum: RAD and IRBBB type RVH (RV volume overload) in ≈ 60%
- Primum: LAFB (almost 100%) ± IRBBB (depending on shunt magnitude)
- Sinus Venosus: Ectopic atrial rhythm (inverted P waves II, III, AVF in ≈30%)

19 yo F: Ostium Secundum ASD, L→R Shunt
rsR' in V1 = RV Outflow Tract Hypertrophy

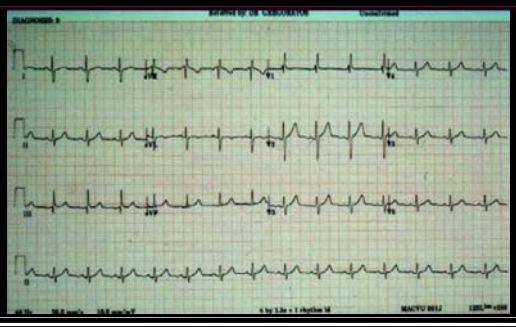

ECG Findings in VSD

- LVH or BVH depending on site of the VSD and magnitude of the L-R shunt
- RVH (usually severe type A) with pulmonary vascular disease (Eisenmenger syndrome)

ECG of 44 YO Man with VSD and L-R Shunt (Qp:Qs= 1.9)

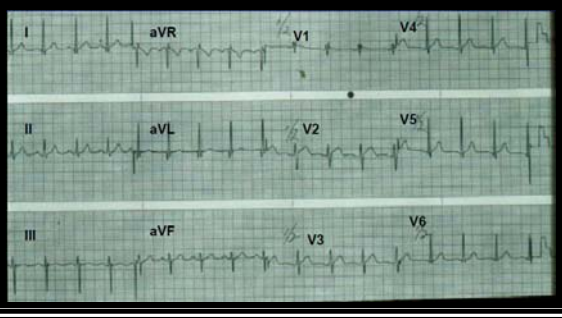

16 yo Male with VSD and Eisenmenger Syndrome: RAD, RVH with 20 ST-T abnormality

Valvar Pulmonic Stenosis ECG: 40 yo Man (RV systolic pressure 70 mmHg)

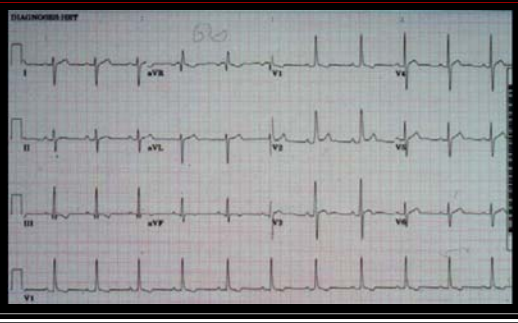

Thanks for Your Attention