

CASE CONFERENCE

CR蘇鈺鋒
Supervisor VS林立偉
2013/08/19

PATIENT DATA

- 43 y/o, male
- Date: 2013/XX/XX, 08:38
- E4V5M6
- TPR: 36/76/20 BP:156/102 mmHg
- SpO2: 100% 痛苦指數: 7
- 檢傷主訴: 腹痛
- Triage: 3

HISTORY

- **Chief Complaint:** epigastric pain after awaking this morning
- Radiated to back
- Upper back or chest pain (-)
- No N/V/D
- 三天會喝保力達B
- GB stone hx ?

Past History

- Allergy: aspirin · 止痛針
- CAD s/p stent

PHYSICAL EXAMINATION

- Cons: clear
- Chest: BS: clear
- Abdomen:



IMPRESSION:

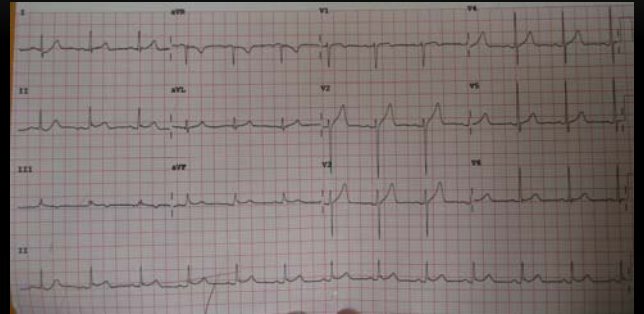
- r/o ileus
- r/o pancreatitis
- r/o ACS

INITIAL MANAGEMENT

day1 08:55

- EKG
- CXR, KUB
- Hb, WBC/DC, PLT
- Glu, Cr, AST, Lipase, T-bil, troponinI
- PT/ aPTT
- NPO
- N/S run 80 cc/hr
- Morphine 5mg iv st
- U/A

EKG



CXR

KUB

LAB DATA

CBC/DC		PT/aPTT		Biochemistry	
WBC ($\times 10^3/\mu\text{L}$)	5.9	PTp	9.7	GLU (mg/dL)	145
RBC ($\times 10^6/\mu\text{L}$)		PTc	10.2	GOT (U/L)	25
Hb (g/dL)	15.9	PT (INR)	0.95	BUN (mg/dL)	
HCT (%)		PTTp	33.5	Cr (mg/dL)	0.7
MCV (fl)		PTTc	32.8	Na (meq/L)	140
MCH (Pg)				K (meq/L)	4.2
MCHC (%)				T-bil (mg/dL)	0.3
PLT ($\times 10^9/\mu\text{L}$)	222			Lipase (U/L)	35
Seg (%)	63.6			Troponin-I ($\mu\text{g/dL}$)	0.016
Lymph (%)	26.9				
Mono (%)	6.8				
Eosin (%)	2.2				
Band (%)	0				

BEDSIDE ECHO

- r/o GB sludge
- No AAA
- 坐著照，不準

EB COURSE

- Still severe back pain
- Need to aorta CT to r/o DAA

AORTA CT

DISCUSSION