

日期

2010年 5月 8日

內容摘要：

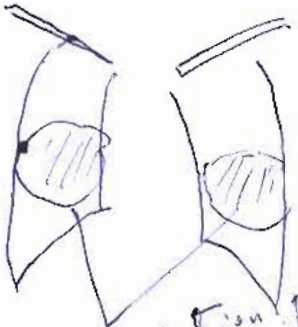
- (填寫說明：1. 如有附件請註明，如簡報檔、全文檔等
- 2. 需有問題與討論：請註明姓名並包含醫學倫理及 EBM 之應用
- 3. 需有總結，請註明做結論者【主持人】姓名
- 4. 請自行編排頁碼)

topic: case conference
 主持人: CR 陳欣全 / F 黃品達
 地點: B2 同新園
 記錄: R1 徐英洲

- Q1 CR 陳欣全: fever, dyspnea 除 lung focus 還有其他 D.D.?
- A1 Int 張維智: metabolic, severe sepsis
- Q2 CR 陳欣全: fever 還要問哪些 history?
- A2 R1 蘇銘鋒: occupation, travel history, contact history?
- Q3 CR 陳欣全: 如懷疑 TB 還要問哪些症狀
- A3 R1 徐英洲: chronic cough, hemoptysis, body weight loss
- Q4 CR 陳欣全: Blood gas analysis?
- A4 PG 徐智鵬: a respiratory alkalosis with hypoxia.
- Q5 CR 陳欣全: Initial impression?
- A5 R1 蘇銘鋒: pneumonia, suspect TB. Acute or chronic renal insufficiency?
- Q6 F 黃品達: D.D. mass with pneumonia?
- A6 R1 徐英洲: airbronchogram → pneumonia, 變異性, 散佈性
- Q7 CR 陳欣全: Admission diagnosis?
- A7 PG 楊智要: pneumonia, Acute or CRF, Normocytic Anemia, Hypertension
- Q8 CR 陳欣全: renal failure type?
- A8 Int 張維智: FeNa 18...%, renal type
- Q9 F 黃品達: pulmonary renal syndrome treatment?
- A9 R1 徐英洲: steroid, immuno suppressant, Antibiotics
- Q10 CR 陳欣全: Anti: cause?
- A10 PG 徐智鵬: Cravit → Imipenem → Meropenem → Teicoplanin

內容摘要 (續):

CXR -



consolidation pneumonia
1/3 malignancy
1/3 TB

Image reviewed >
Non-contrast chest CT



suspect Necrotizing pneumonia

Consolidation

< EBM topic >

- pulmonary renal syndrome
- => diffuse alveolar hemorrhage and glomerulonephritis occurring simultaneously
- microscopic polyangiitis
- => $\frac{1}{10000} - \frac{3}{1000}$ male slightly affected more than female

< VS comment >

- Atypical finding or strange appearance
- => consider metabolic or autoimmune

記錄 R. 符吳明